The Journal of Arthroplasty 29 (2014) 1063–1066

Contents lists available at ScienceDirect

The Journal of Arthroplasty

journal homepage: www.arthroplastyjournal.org

Cementless Hip Arthroplasty in Paget's Disease at Long-Term Follow-Up (Average of 12.3 Years)

Arjuna M. Imbuldeniya, MBBS, BMed.Sci (Hons), FRCS (Tr&Orth), Stephen M. Tai, MBBS, BSci(Hons), FRCS (Tr& Orth), Tariq Aboelmagd, William L. Walter, FRACS, FAOrthA, PhD, William K. Walter, MBBS, FRACS, FAORthA, Bernard A. Zicat, MD, FRACS, FAOrthA

Specialist Orthopaedic Group, North Sydney, New South Wales, Australia

ARTICLE INFO

Article history:
Received 20 September 2013
Accepted 14 October 2013

Keywords:
hip arthroplasty
Paget's disease
cementless fixation
hydroxyapatite

ABSTRACT

We present a long-term follow-up report of 33 cementless total hip arthroplasties in 27 patients who have an established diagnosis of Paget's disease. The medium term results of this series were reported in 2007 (Lusty et al. *Journal of Arthroplasty*. 2007;22:692). Fourteen cases were available for follow-up at an average of 12.3 years (range 10–17). Harris Hip scores improved from 56/100 preoperatively (16–98/100) to 83/100 post operatively (72–90/100). All surviving components were radiographically ingrown. Based on these findings, cementless total hip arthroplasty has a good long-term outcome in Paget's disease.

The long-term results of cementless arthroplasty in Paget's disease is not well documented. We present the results of a series of patients with Paget's disease at a minimum 10-year follow-up. We previously reported on this cohort at 2 to 14 years (mean 6.7 years) [1]. In that initial series, a total of 33 cases in 27 patients were identified, and after excluding patients who had died, had revision surgery for any cause or were lost to follow up, 23 cases in 18 patients were available for follow up. After 7 years of follow up, there was an 86% survival rate with revision for any cause (95% confidence interval 65–99%). The survival rate for revision due to asceptic loosening was 99.5% at 7 years (95% confidence interval 77–100%). None of the acetabular components showed any osteolysis or lucent lines and none had migrated. All stems and cups appeared ingrown on radiographic review. Heterotopic bone was seen in 12 cases, 11 were Brookers grade 1 or 2, and the remaining case was grade 3.

We hypothesize that cementless hip arthroplasty in Paget's disease continues to give good clinical results and durable fixation at a minimum of 10 years.

Materials and Methods

We retrospectively reviewed 33 consecutive patients from our database who had a primary hip arthroplasty between February 1998 and June 2003 with an established preoperative diagnosis of Paget's disease. All patients were operated on by the senior author (WKW) in a low flow vertical airflow theatre through a posterior approach. The pattern of Pagetic involvement was 23 femora, 24 acetabuli with both areas involved in 14 cases. The average age at surgery was 75 years (range, 63–85 years), 56% were male, the average weight was 71 kg (range 51–94).

Graduated compression anti-embolism stockings and chemical prophylaxis for deep vein thrombosis were routine. Patients were mobilized early and allowed to mobilise full weight bearing in all cases except where an osteotomy was performed.

Five cases (21%) had a step-cut osteotomy and autologous cancellous bone graft at the apex of a femoral deformity. All these cases were stabilized with an S-ROM stem (DePuy, Warsaw, IN) and went on to bony union. Five cases (21%) had morcelised cancellous autograft for acetabular cysts or protrusion.

All patients had prophylactic broad spectrum antibiotics for 48 hours postoperatively. Femoral components included 8 ABG I, 14 ABG II, 2 Osteonics (Stryker Howmedica Osteonics, Mahwah, NJ), 6 S-ROM with a hydroxyapatite coated proximal sleeve and 3 S-ROM with a porous coated proximal sleeve (DePuy, Warsaw, IN).

Acetabular components included 4 ABG, 20 ABG II, 3 Osteonics (Stryker Howmedica Osteonics, Mahwah, NJ), 3 Implex (Implex,

The Conflict of Interest statement associated with this article can be found at http://dx.doi.org/10.1016/j.arth.2013.10.015.

Reprint requests: Arjuna M. Imbuldeniya, MBBS, B.Med.Sci (Hons), FRCS (Tr&Orth), Specialist Orthopaedic Group, Mater Clinic Suite 1.08, 3–9 Gillies Street, North Sydney, New South Wales 2060, Australia.

0883-5403/2905-0039$36.00/0 – see front matter.
http://dx.doi.org/10.1016/j.arth.2013.10.015

Allendale, NJ), 1 Harris Galante, 1 Harris Galante II (Zimmer, Warsaw, IN) and 1 S-ROM Gripper cup (DePuy, Warsaw, IN).

Follow-Up

Patients were initially seen at 6 weeks, then at 1, 3, 5, 10, 15 and 20 years. At clinical review, patients filled in a questionnaire based on the "Standard System of Terminology for Reporting Results" [2] which included a modified Harris hip score [3]. Outcome measures included assessment of thigh and groin pain, grading the pain in each area as none, mild, moderate or severe. The operating surgeon (WKW) examined the patients for their range of motion, the presence of a limp and leg length discrepancy.

An anteroposterior and a lateral radiograph of the hip were taken at each review. Acetabular migration was measured using the method of Nunn et al [4]. Acetabular component fixation was assessed using DeLee and Charnley's zones [5]. The femoral component fixation was assessed using the method described by Engh et al [6]. This involves comparing immediate postoperative and most recent radiographs for migration, cortical hypertrophy, stress shielding, endosteal spot welds, and pedestal formation. Heterotopic bone formation was scored according to Brooker et al [7].

All radiographic and clinical scores were performed prospectively and recorded on our database.

Results

Of the 27 patients (33 hips), 5 patients (6 hips) were lost to follow-up despite repeated attempts to contact them. Six patients (7 hips) died before the minimum 10 year follow-up, all for reasons unrelated to their surgery. The high death rate, as mentioned in our earlier report [1] reflects the advanced age of our study population. Of the 11 patients (13 hips) without 10 year follow up, all implants were unrevised and problem free at last review (mean 5.3 years radiographic follow up, and mean 6 years clinical follow up). 5 patients (6 hips) had revision surgery (mean 9.7 years, range 0.8 years to 14 years). After excluding patients revised, lost or died, 11 patients (14 hips) were available for clinical and radiographic follow-up at a minimum of 10 years.

Complications

Three cases described previously [1] had revision surgery before the minimum 10 year follow up. A further 3 cases since this time have been revised and are described below.

The first case, an 80 year old woman with Paget's disease affecting her femur and acetabulum, had a hip arthroplasty with an ABG II femoral component, an ABG II 'no hole' acetabular cup, and a 28 mm cobalt chrome on ultra-high molecular weight polyethylene (UHMWPE) bearing. Her hip was revised 17.3 years after surgery for extensive polyethylene wear and associated granuloma formation. Extensive bone loss from the ischium and greater trochanter was packed with morcelised femoral head allograft and cancellous autograft. As the stem was solidly fixed, the cup was revised and delta ceramic bearing surfaces were used with a 32 mm head. As with all our patients requiring bone graft, 6 weeks of touch weight bearing was advised.

The second case was an 82 year old male with Paget's disease affecting his femur and acetabulum (Fig. 2). His hip was revised at 14 years for pain and aseptic loosening secondary to polyethylene wear. His S-Rom HA coated stem was well fixed and the previous step cut femoral osteotomy to correct an anterolateral bow was well healed. The Implex one piece cup was removed, the osteolytic lesions in the acetabulum were grafted with cancellous autograft and an extensive collection of granulomatous tissue in the psoas bursa excised. The 28 mm ceramic on polyethylene bearing was revised to 32 mm alumina ceramic on ceramic.

The third case was in the same male patient who had his other hip revised 1 year later, 14 years after surgery for extensive polyethylene liner wear (Fig. 2). Osteolysis was found in the ischium with granuloma formation. He had an ABG II stem in situ which was stable and no previous osteotomy. The ABG II cup was revised with cancellous autograft to fill the defect. The 28 mm metal on polyethylene bearing surfaces were revised to 32 mm delta ceramic on ceramic.

Clinical evaluation

The average time to clinical evaluation was 12.3 years (10.3–17 years). At 10 years follow up, there is an 86% (95% confidence interval 65–95%) survival rate for both stem and cup with revision for any cause, treating the 5 lost patients as censored data with 11 patients (14 cases) at risk (Fig. 1). The survival rate for revision due to asceptic loosening alone is 95.5 at 10 years (95% confidence interval, 77–99% using the same criteria). Mild or moderate thigh pain was reported by the same patients as mentioned in our original study [1]. The mean Harris hip score improved from 56 (range 16–98) to 83 (range 72–90) at latest follow-up with 73% good or excellent results. There were no cases of dislocation and no cases of sepsis.

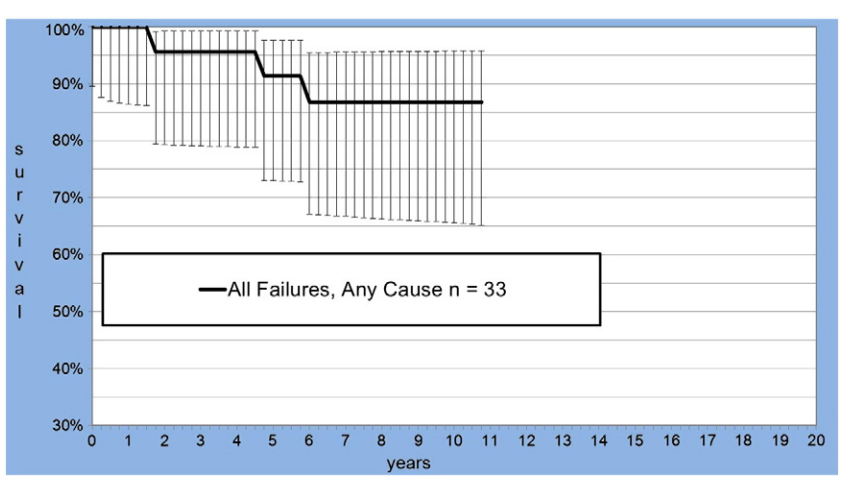

Fig. 1. Kaplan-Meier survivorship of cup and stem with end points revision for any cause, where loss to follow up is censored.

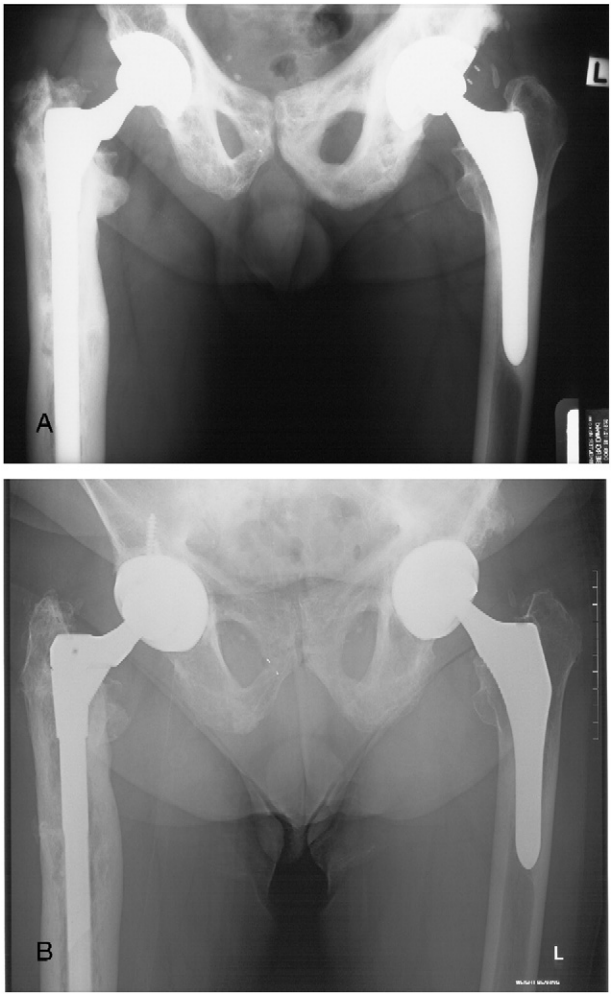

Fig. 2. An 82 year old male patient with Paget's featured in our previous report with disease affecting both hips. (A) 12 years post right total hip arthroplasty and 11 years post left total hip arthroplasty. Note spot welds attached to femoral components and healed right femoral osteotomy. (B) Five years post revision of right acetabular component and 4 years post revision of left acetabular component for polyetheleyene wear. The right S-ROM femoral component has survived for 19 years and the left ABG II femoral component for 18 years.

Radiographic evaluation

The average time to radiographic evaluation was 11.7 years (range 10.3–14.6 years). The mean linear wear was 2.8 mm. Only 1 (7%) of the acetabular components showed any osteolysis, or lucent lines, and none of them had migrated. All 14 stems appeared in-grown on radiographic review, with no stem migration present (Fig. 1). Heterotopic none formation was common and seen postoperatively in 5 cases (45%), 4 were Brooker's grade 1 and the 5th was grade 2.

Discussion

Since our original report submitted 7 years ago [1], 6 further patients (8 hips) in total were unavailable for clinical or radiographic follow-up at a minimum of 10 years. Two patients (3 hips) were lost to follow-up, 2 patients (2 hips) died and 2 further patients (3 hips) described above were revised. All revisions were for osteolysis behind the acetabular cups secondary to wear debris from the UHMWPE liners used at time of primary procedure between 14 and 17 years ago. It is now our practice to remove the worn polyethylene liner and old on-growth cup routinely where there is extensive osteolysis, especially behind the cup as in the cases described. We then pack bony defects in the acetabulum with cancellous autograft and allograft prior to implantation of a new HA ingrowth cup. The bearing surfaces are changed to ceramic on ceramic with a larger head size. Despite this, only one of the uncemented cups was found to be loose at time of revision. The remaining 14 femoral and acetabular components have demonstrated no clinical or radiographic loosening at a mean of 12.3 years (range 10–17 years). Five cases (15%) had corrective step cut diaphyseal femoral osteotomies. All osteotomies were stabilized with a modular, cementless metaphyseal proximal loading stem (S-ROM, DePuy, Warsaw, IN) and went on to bony union. 3 patients reported a good result, and 2 reported an excellent result using the modified Harris Hip Score.

Cementless implants have a theoretical advantage over cemented implants. Cement penetration and interdigitation may be limited in Pagetic bone which is typically sclerotic and more prone to bleeding. However it is not known if the altered morphology of the bone will allow for sufficient bony ongrowth onto cementless stems. Thus far, promising results have been reported with the use of uncemented components, though the longest series we could find reported 8 year results [8–10]. One report advocated the use of pre-operative bisphosphonates with cementless components to reduce disease activity. This was also associated with reduced intra-operative blood loss [11]. In contrast, the results of cemented hip arthroplasty have an overall increased incidence of symptomatic and asymptomatic radiographic loosening, though length of follow up as expected is generally longer in these reports and may account for this [12–16].

The overall incidence of heterotopic bone formation in our patients evaluated after 10 years was 45%. This is in keeping with previous reports [9–11,13,15] and it is still unclear how the surgical approach to the hip affects this. It is also unclear as to how best to prevent it in terms of dose and timing of radiation and chemoprophylaxis [17,18].

Conclusion

This brief follow-up report of a small series of patients is the longest published follow up of cementless hip implants in a Paget's cohort. We demonstrate that aseptic loosening is not a concern at long-term follow-up and patients continue to have a good outcome.

Acknowledgments

The authors wish to thank Sharon Wales and Lyn McDonald for their continuing assistance with data collection.

References

1. Lusty PJ, Walter WL, Walter WK, et al. J Arthroplasty 2007;22:692.
2. Johnson RC, Fitzgerald Jr RH, Harris WH, et al. Clinical and radiographic evaluation of total hip replacement. A standard system of terminology for reporting results. J Bone Joint Surg Am 1990;72:161.
3. Harris WH. Traumatic arthritis of the hip after dislocation and acetabular fractures: treatment by mold arthroplasty. An end-result study using a new method of result evaluation. J Bone Joint Surg Am 1969;51:737.
4. Nunn D, Freeman MA, Hill PF, et al. The measurement of migration of the acetabular component of hip prostheses. J Bone Joint Surg Br 1989;71:629.
5. DeLee JG, Charnley J. Radiological demarcation of cemented sockets in total hip replacement. Clin Orthop Relat Res 1976:20.
6. Engh CA, Massin P, Suthers KE. Roentgenographic assessment of the biologic fixation of porous-surfaced femoral components. Clin Orthop Relat Res 1990:107.
7. Brooker AF, Bowerman JW, Robinson RA, et al. Ectopic ossification following total hip replacement. Incidence and a method of classification. J Bone Joint Surg Am 1973;55:1629.
8. Hozack WJ, Rushton SA, Carey C, et al. Uncemented total hip arthroplasty in Paget's disease of the hip: a report of 5 cases with 5-year follow-up. J Arthroplasty 1999;14:872.
9. Parvizi J, Schall DM, Lewallen DG, et al. Outcome of uncemented hip arthroplasty components in patients with Paget's disease. Clin Orthop Relat Res 2002:127.
10. Kirsh G, Kligman M, Roffman M. Hydroxyapatite-coated total hip replacement in Paget's disease: 20 patients followed for 4–8 years. Acta Orthop Scand 2001;72:127.
11. Wegrzyn J, Pibarot V, Cahpurlat R, et al. Cementless total hip arthroplasty in Paget's disease of the bone: a retrospective review. Int Orthopeadics 2010;34:1103.
12. Merkow RL, Pellicci PM, Hely DP, et al. Total hip replacement for Paget's disease of the hip. J Bone Joint Surg Am 1984;66:752.

13. McDonald DJ, Sim FH. Total hip arthroplasty in Paget's disease. A follow-up note. J Bone Joint Surg Am 1987;69:766.
14. Ludkowski P, Wilson-MacDonald J. Total arthroplasty in Paget's disease of the hip. A clinical review and review of the literature. Clin Orthop Relat Res 1990;255:160.
15. Stauffer RN, Sim FH. Total hip arthroplasty in Paget's disease of the hip. J Bone Joint Surg Am 1976;58:476.
16. Sochart DH, Porter ML. Charnley low-friction arthroplasty for Paget's disease of the hip. J Arthroplasty 2000;15:210.
17. Ferguson DJ, Itonaga I, Maki M, et al. Heterotopic bone formation following hip arthroplasty in Paget's disease. Bone 2004;34:1078.
18. Lorio R, Healy WL. Heterotopic ossification after hip and knee arthroplasty: risk factors, prevention, and treatment. J Am Acad Orthop Surg 2002;10:409.